

Technical advance

Open Access

A novel surgical technique to localize small enteropouch fistula

Abbas Basiri¹, Emadoddin Mo'oudi², Hamed Akhavizadegan*² and Naser ShakhsSalim²

Address: ¹Professor of Urology, Urology/Nephrology Research Center, Shaheed Labbafinejad Hospital, Shaheed Beheshti University of Medical Sciences, Tehran, Iran and ²Resident of Urology, Shaheed Labbafinejad Hospital, Shaheed Beheshti University of Medical Sciences, Tehran, Iran

Email: Abbas Basiri - abbasbasiri@hotmail.com; Emadoddin Mo'oudi - celia16375@yahoo.com; Hamed Akhavizadegan* - hamed_akhavizadegan@yahoo.com; Naser ShakhsSalim - gandom_7@yahoo.com

* Corresponding author

Published: 30 November 2005

Received: 23 March 2005

BMC Urology 2005, 5:16 doi:10.1186/1471-2490-5-16

Accepted: 30 November 2005

This article is available from: <http://www.biomedcentral.com/1471-2490/5/16>

© 2005 Basiri et al; licensee BioMed Central Ltd.

This is an Open Access article distributed under the terms of the Creative Commons Attribution License (<http://creativecommons.org/licenses/by/2.0>), which permits unrestricted use, distribution, and reproduction in any medium, provided the original work is properly cited.

Abstract

Background: One of the rare complications of ileal neobladder after radical cystectomy is pouch-to-intestine fistula. There isn't a classic method to intraoperative diagnosis of small fistula.

Case presentation: An entero-pouch fistula was occurred in a patient after radical cystectomy with illeal orthotopic pouch. Because of failed conservative management, the patient was candidate for surgery. The hidden small fistula in the small intestine was diagnosed by high intraluminal hydrostatic pressure (by intraluminal saline injection).

Conclusion: Intraoperative diagnosis the intestinal opening of a small fistula is very important. At the time of surgery if the fistula tract becomes open (during releasing the adhesions), it may leak in the peritoneum in postoperative period. Intraluminal high pressure is a useful method for intraoperative small hidden intestine opening.

Background

One of the complications of ileal neobladder after radical cystectomy is pouch-to-intestine fistula [1]. To date cases with enteropouch [2], enteroconduit [3] and ureteroenteric [4] fistulae have been reported. Patients more often have a history of irradiation [2], but there have been cases observed without it too [5]. Conservative management and surgery both have been used to treat such fistulae [5,6]. To our knowledge there is no published report on the surgical technique used to treat enteropouch fistulae. We report a novel intraoperative technique to identify non-visible fistula.

Case presentation

A 52-year-old male with muscle invasive TCC (grade III) had undergone radical cystectomy and ileal orthotopic

pouch reconstruction. Anastomosis of small intestine was performed in two layers (first running chromic and second with simple separate silk sutures). On the 10th day after the operation while the patient was on normal diet and had no abdominal symptom or defecation disorder, fecaloid materials were found in urine and drained secretions. Enteropouch and enterocutaneous fistulae were confirmed using oral activated charcoal. The patient was put on fasting and TPN. Antibiotic therapy was initiated, consequently, urinary fecaloid drainage and enterocutaneous fistula improved. However enteropouch fistula remained unresolved even after one month of conservative management. The patient was discharged with free urinary drainage and low residue diet for another month, but the fistula persisted. Upper GI series revealed no pertinent information (fig. 1), but pouchogram (fig. 2) revealed that the fis-

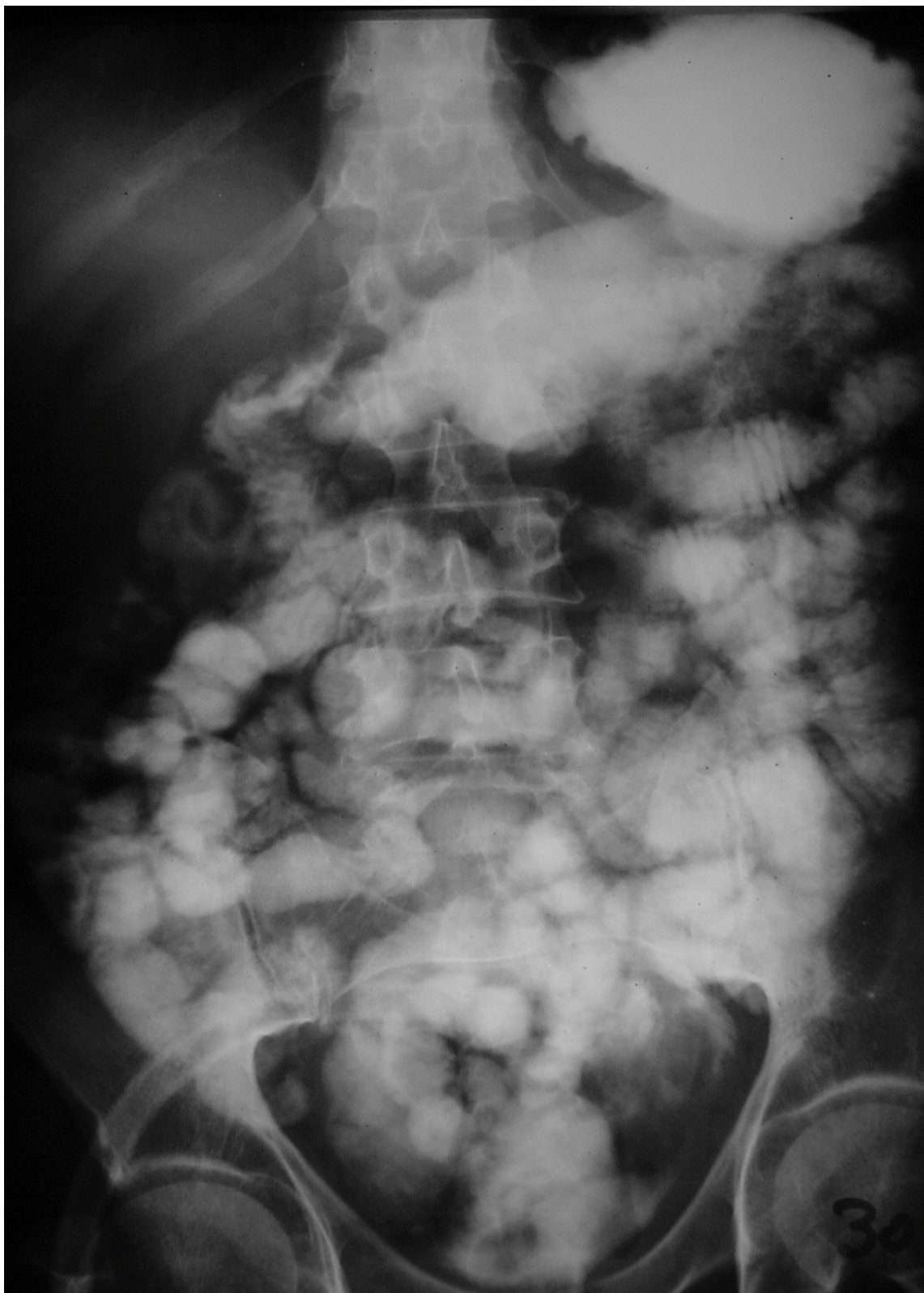


Figure 1
Upper GI series of the patient with entero-pouch fistula.

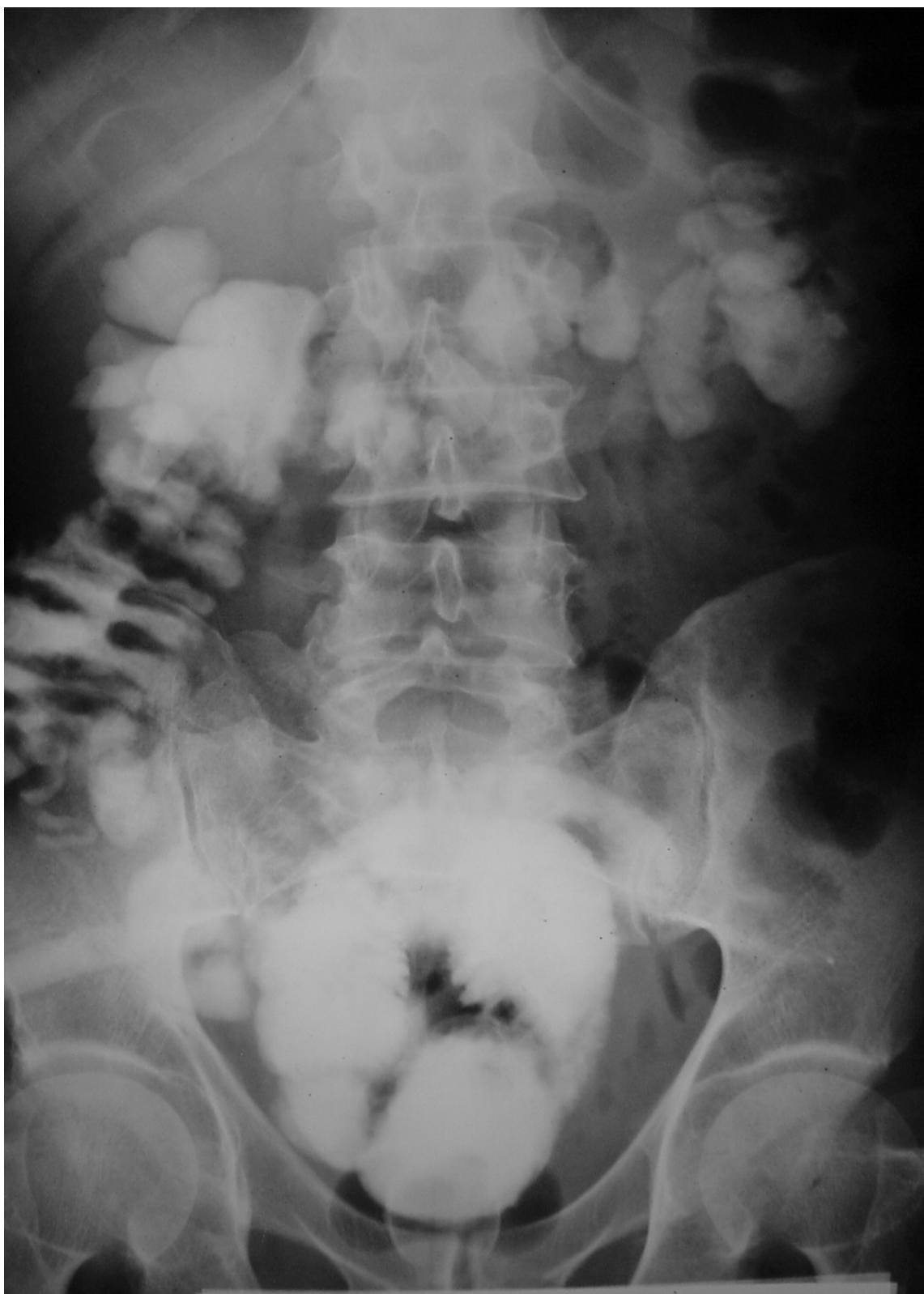

Figure 2
Pouchogram of the patient with entero-pouch fistula.

tula was proximal to the ileocecal junction and most probably on the bowel anastomosis.

Performing surgery, via previous surgical scar (lower mid-line) all adhesion bands were released and anastomosis (defined by silk sutures) was separated from the pouch, but no fistula was revealed. Thus, with intestine clamped on each side of anastomosis and saline was injected to the lumen, intraluminal pressure increased gradually and fistula appeared by leaking fluid through it.

Fistula repair was done in two layers (after freshening of its edges) in transverse fashion to decrease the risk of stricture. Omentum was interposed between the pouch and fistula without tension. The patient was on TPN and NPO for 5 days and free drainage for two weeks. After two weeks pouchogram was performed and no fistula was seen subsequently the patient was discharged with clean intermittent catheterization. Follow-up up to one year was indicative of favourable outcome.

Discussion

Enteropouch fistula is a rare complication after supravescical urinary diversion [5]. Other than surgery, diverticulitis, colorectal malignancy, radiation and Crohn's disease have become the most common aetiology of entero-urinary fistula [7].

In other case reports; fistula was detected three weeks after surgical operation [5,6], while fistula manifestations were observed 10 days after surgery in our patient. According to the published reports, symptoms are watery diarrhea, mild abdominal symptoms (nausea, vomiting, and dehydration, but normal physical examination), gas in the pouch (diagnosed by KUB) and fecaluria [2,6]. In our case the only symptom was fecaluria. All the researchers have mentioned that upper GI series, barium enema, and CT scan are not helpful and the best diagnostic modality is pouchogram [2,6], as it was in our patient. Occasionally, clinical diagnosis in borderline cases is difficult [8]. Some investigators use charcoal [9], methylene blue [8], poppy seed [8], and urine cytology in order to confirm enteropouch fistula diagnosis [10].

The conservative management which is indicated in cases with no sepsis, no obstruction, and no organ impairment and with a normal nutritional status, consists of hyper-alimentation, fasting or low residue diet and continuous urinary drainage [7].

Our review results contained cases reported as resistant to conservative management, who were treated surgically [6]. However, the surgical technique used was not elaborated in any of the studies. To our experience, during the operation after releasing all adhesion bands between the

pouch and intestinal loops, it's of utmost importance that intestinal opening be defined using intestinal compression in both sides of anastomosis. Otherwise, there is a high probability of inter-loop abscess formation due to the intraperitoneal bowel perforation, which may lead to a high mortality rate.

Conclusion

Oral administration of activated charcoal is a useful method to help diagnosis of enteropouch fistula. Also, pouchogram is the best diagnostic test.

During the operation, examining the anastomotic site and then all sites of adhesion between intestine and pouch with high intraluminal pressure is an eligible method to detect fistula opening in the intestine.

References

- Hautmann RE, Miller K, Steiner U, Wenderoth U: **Ileal neobladder: 6 years of experience with more than 200 patients.** *J Urol* 1993, **150**(1):40-5.
- Tarter TH, Kawachi MH, Wilsas TG: **Entero-pouch fistula: a rare complication of right colon continent urinary diversion.** *J Urol* 1995, **154**(2):364-366.
- McCallin WA, Wison BG, Kennedy JA, Keen PF: **Ileal conduit-enteric fistula.** *BJU* 1993, **71**:230.
- Ornellas AA, Correia Seixas AL, Marota A, Winesnesky A, Campos F: **Uretero-ureterocolic fistula 10 months after enterocystoplasty.** *Prog Urol* 1994, **4**(1):87-90.
- Ng CS, Klein EA: **Conservative management of an ileal neobladder-enteric fistula.** *Urology* 1999, **54**(2):366.
- Deliveliotis C, Picramenos D, Macrichoritis C, Kiriazis P, Kostakopoulos A: **Ileal neobladder-enteric fistula, a rare early post operative complication treated conservatively.** *Br J Urol* 1995, **76**(3):407-408.
- Shackley DC, Brew CJ, Bryden AA, Anderson ID, Carlson GL, Scott NA, Clarke NW: **The staged management of complex entero-urinary fistulae.** *BJU Int* 2000, **86**(6):624-9.
- Schwaibold H, Popiel C, Geist E, Hartung R: **Oral intake of poppy seed: a reliable and simple method for diagnosis vesicoenteric fistula.** *J Urol* 2001, **166**(2):530-531.
- Pontari MA, McMillen MA, Garvey RH, Ballantyne GHI: **Diagnosis and treatment of enterovesical fistula.** *Am Surg* 1992, **58**:258.
- Daniels IR, Bekdash B, Scott HJ, Marks CG, Donaldson DR: **Diagnostic lessons learnt form series of enterovesical fistula.** *Colorectal Disease* 2002, **4**(6):459-462.

Pre-publication history

The pre-publication history for this paper can be accessed here:

<http://www.biomedcentral.com/1471-2490/5/16/prepub>